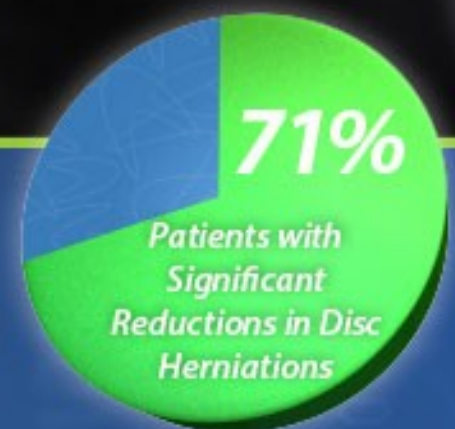

Research Proves Spinal Decompression

Reduces Disc Herniation Size up to 90% In a Majority of Patients While Decreasing Pain 90%



MRI Evidence of Nonsurgical,
Mechanical Reduction,
Rehydration and Repair of the
Herniated Lumbar Disc Study



STUDY: MRI Evidence of Nonsurgical, Mechanical Reduction, Rehydration and Repair of the Herniated Lumbar Disc

Abstract

Simple pelvic traction gives inconsistent relief to herniated lumbar disc sufferers. A new decompression table system applying fifteen 60-second tractions of just over one half body weight in twenty 1/2 hour sessions was reported to give good or excellent relief of sciatic and back pain in 86% of 14 patients with herniated discs and 79% of 8 with facet joint arthrosis. (Shealy, C.N., Borgmeyer, V., Am J Pain Management 1997; 7:63-65). Herniated and degenerated discs can be shown at discography-discoanometry to have elevated intradiscal pressures made even worse by sitting and standing, thus preventing proper disc nutrition. Therefore decompressing the over pressurized disc should allow for healing and repair of disc prolapse, herniation and annulus tears. Serial MRI imaging of 20 patients treated with the decompression table shows in our study up to 90% reduction of subligamentous nucleus herniation in 10 of 14. Some rehydration occurs detected by T2 and proton density signal increase. Torn annulus repair is seen in all. Transligamentous ruptures show lesser repair. Facet arthrosis can be shown to improve chiefly by pain relief. Follow up studies for permanency or relapses are in progress.

Study

INTRODUCTION
Standard pelvic traction has been unsatisfactory in relieving sufferers with herniated lumbar discs and radiculopathy achieving, at best, about 25% effectiveness with little in the way of imaging change in the status of the disc. A new mechanical distraction system, the decompression reduction and stabilization system (DRS), was described by Dr. Norman Shealy¹ to give 50% improved outcome over conventional treatment with standard pelvic traction. Seventy-five percent of subjects improved clinically, and in one case, an L5/S1 disc herniation on mid-sagittal MRI was shown to have a 50% reduction in size of the herniation after 20 distraction treatments. During distraction a 7mm separation of the L5 from the S1 vertebral body was demonstrated.²

The present study was undertaken to determine whether clinical betterment can be correlated directly to improvement in MRI image and whether MRI findings shed any light on the mechanism of improvement.

That an abnormal pressure is present in an abnormal disc can be appreciated often at discogram and discoanometry, sometimes elevated and sometimes reduced. In discs with relatively intact annular envelopes, the pressure can be found to be elevated at rest over normal values, especially in the sitting position. Yet in discs with radial tears or fissures there can be a demonstrated leakage of the discs and therefore at the initial of contrast infusion on discography, opening pressures are actually lower than normal. They become even lower at the end of infusion because of leakage of contrast which can be demonstrated by x-ray of

CT.³ One postulate is that in the well-contained abnormal disc an abnormally elevated pressure results in faulty diffusion of nutrients from surrounding vessels in bone and the epidural space into the nucleus with inadequate patching or repair of the fissured annulus. In the discs with low initial pressure from torn annulus, leakage would impair retention of nutrients.⁴ Thus restoring the integrity of the annulus is likely an important mechanism of healing the disc and helping to restore the integrity of gel pressure and chemistry. Adequate distraction treatment to promote lowering of intradiscal pressure for disc repair has been emphasized by Nachemson and his group for over 3 years.^{5,6}

Neurosurgeons Ramos and Martin⁷ at percutaneous discectomy applied lumbar distraction and showed that it is possible to lower elevated intradiscal pressure in herniated L4/5 discs into the negative range of -100 to -150mm mmHg using as little as 90 lbs of pelvic traction. In theory, such negative pressures would encourage fluid entry to rehydrate the nucleus and perhaps repair the injured annulus. Onel and colleagues⁸ demonstrated by CT significant retraction of lumbar disc herniation in 21 of 30 patients using a continuous lumbar distraction for 40 minutes at 60-80% body weight. They hypothesized that a significant negative pressure applied to the disc space had improved blood flow from adjacent bony end plates and epidural vessels to provide healing fluids and nutrients to the disc.

The present study was done to determine whether serial MRI imaging can shed any light on the mechanism of improvement in lumbar disc herniation treated with an adequate course of mechanical distraction delivered in an optimal manner as possible.

METHODS AND PATIENTS
Twenty patients with lumbar radiculopathy documented on clinical examination and electromyography were treated on the DRS decompression table system, a mechanical, split-table distraction device. Subjects were placed supine, knees flexed over a cushion with chest harnessed to the head of the table. The lumbar spine was then distracted at one-half body weight plus 10 to 20 lbs by a pelvic harness belted to a tower that could be raised or lowered to give a focused angle optimal to the disc space being treated.

Twenty lumbar decompression treatments were given over a four to five week period to 13 patients, and a double course of 40 treatments in 10 weeks were given to 2 additional patients with very large disc herniations. These did show continual slow improvement. In each session 20-50 seconds, full weight distractions were alternated with 30 seconds of relaxation to 50 pounds. Distraction angle on the pelvic harness was adjusted from 10 degree for L5/S1 to 15-20 degree for L4/5 herniations and above. Distraction angle adjustments towards adjacent posterior vertebral margins were done to promote optimal recession of disc protrusion by pulling these margins apart. Subjects were twelve males and eight females, ages 26 to 74. Radiculopathy, confirmed by EMG, was from disc herniation in 14 patients and from minor disc protrusion plus foraminal stenosis, facet arthropathy and lateral spinal stenosis in six. Significant herniations treated were 4-10mm in size, and all were subligamentous. Six herniations were at L5/S1, six at L4/5, and one each at L3/4 and L2/3. An MRI on either high or midlevel views were performed within four weeks before and after treatment. Clinical status was assessed before,

during, and after treatment using standard anal og pain scale measurements of lumbar mobility and full neurologic exam results.

MRI OUTCOMES

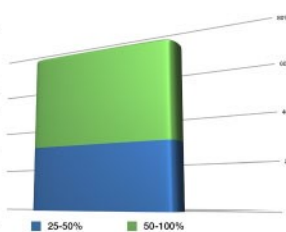
Disc herniations reduced significantly in 10 of 14 subjects. Large reductions of 50-100% were observed in six herniations, and 25-50% herniations in four. Reduction in two smaller herniations resulting in marked clinical improvement occurred in disc protrusions placed in the lateral recess in what could be called the "critical zone" for the nerve root.

On large disc herniations three showed global reduction of 90-100% after treatment. For example, figure 1 shows a relatively acute disc herniation of under 4 week at the L2/3 level in a 67-year-old man, which resolved completely after 20 DRS treatments in four weeks. Sealing of the torn posterior annulus is observed in the follow-up MRI. Figures 2 and 3 show before and after MRI axial views with complete retraction of disc prolapsed at L5/S1 after distraction. These subjects, a 40-year-old physical education teacher and a 39-year-old female service supervisor, had complete relief of disabling posterior calf pain and of toe flexor weakness. Figure 4 pictures a 60% retraction of a prolapsed disc on the left which had been completely covering the S1 nerve root, the arrow indicating the free space between the retracted disc prolapsed and the now visible S1 nerve root.

This individual, a 28-year-old male chemist having to do heavy maintenance work lifting up to 150 pounds, was returned to full work duty within two weeks after completing treatment as were the subjects in figures 2 and 3. Figure 5 shows a remarkable example of an over 90% reduction of disc herniation in a 40-year-old female dog groomer who had been able to bend at the waist in any direction for three months because of a large L4/5 disc protrusion with L5 radiculopathy and had failed conventional treatment. Her treatment was extended to 40 sessions over 10 weeks. Repeat proton density and a T2 MRI confirmed in this patient (and also in three additional cases in this series) not only a remarkable retraction of the herniated disc but an increase of proton and T2 weighted signals indicating at least some rehydration of the dehydrated nucleus. Also seen is a sealing of the torn annulus at a very unusual "empty pouch sign" between the now restored nucleus and the still bowed over posterior longitudinal ligament. Such a vacated space after disc retraction was seen in two additional cases in this series (not shown). One also noted in figure 5 complete clearing of the "high intensity spot" on the underside of the posterior annulus which was said to represent a healing area in a radial tear (4).

CLINICAL OUTCOMES

Respective of MRI status, all but three patients had significant pain relief and complete relief of weakness when present and of numbness in the leg disappeared in all but one patient who had lateral disc herniation and in two with foraminal stenosis without much herniation. In those patients with disc herniation, 10 out of 14 had 90% improvement in pain and disability, two had roughly 50% relief, and one had only 20% relief. In those patients with foraminal syndrome but without much frank herniation of disc, four had 75-100% improvement in pain, one had 50% relief, and one with severe spinal stenosis had little relief and was sent for surgery. Thus, the degree of clinical improvement roughly followed the MRI changes.



Over 71% of patients experienced at least a 25% decrease in size. Over 40% experienced a decrease of 55% or greater.

DISCUSSIONS

In this study there appeared to be a general correlation between improvement and retraction of the lumbar disc as shown by the MRI. This can certainly be argued strongly for those patients who achieved improvement with near 100% retraction of the herniation. Yet those showing improvement with lesser degree of MRI change might have to be explained in other ways. We could find a freeing up of the nerve root from lateral or foraminal herniations in what could be called "the critical zone" as seen in figure 4. Clinical improvement in those patients with primarily foraminal stenosis or disc space narrowing without much herniation could be explained by joint mobilization in the freeing up of an impacted nerve root or improvement of nerve root circulation by the distraction treatment. Since abnormal disc specimens obtained at surgery lack chondroitin sulfate 6 hydrated content demonstrated by Hutton⁹, the finding of increased proton signal of at least some degree in four of our subjects studied might well be another mechanism of improvement.

The leakage of sulfates and carboxylates through fissures or tears in the annulus is likely not only a cause of signal loss in disc degeneration but could be a cause of nerve root irritation as shown in recent discography studies.¹⁰ We noted very rapid relief of pain occurring in four subjects in this study in as few as the first three sessions. This was very likely occurring before any MRI changes could possibly be seen, although we did not look that early for an MRI change. It is known that prolapsed discs have pain-sensitive nerve ingrowth beyond the normally ensheathed outer third of the annulus into the inner portion and also into the nucleus.¹¹ Immediate local and radicular pain is produced on discogram in contrast injection as well. Therefore, possibly the very early pain relief may be accomplished in segmental distraction by lowering intradiscal pressure enough to cause retreat or to lessen sensitivity of the nerve fibers. A suction effect of the negative pressure applied to the vertebral end plates and intervertebral space can also be thought of as improving the nutrition and leading to the healing of the disc. Disc nutrition comes primarily from the cartilaginous end plate, partly from epidural vessels, and partly through vertebral end plates.¹² Modic et al¹³ showed

that the earliest vertebral end plate change associated with early disc degeneration is hypemia. In fact the type one hyperemic vertebral end plate changes has been shown with high resolution SPECT imaging to occur even before MRI changes in the bone can be appreciated.¹⁴ Thus nutrient delivery to heal an ailing disc is likely a crucial factor in both clinical and an atomic improvement.

LI summary, therefore, the primary mechanism to explain the beneficial efforts of focused high weight distraction treatment on the herniated disc as described in this report is likely to be a lowering of the pressure in the intervertebral disc space to accelerate and promote nutrient diffusion essential to disc repair. The suggestion of Onel⁸ that the beneficial suction effect on the disc space is created by the negative pressure of distract on may well be correct.

The follow up of the 17 patients who showed clinical improvement in the present series at one year revealed only one to have a recurrence. It could be argued that reversing leakage through fissures and tears in the annulus allows the most direct repair of the herniated lumbar disc by promoting fibroblast repair of the inner and outer annulus layers and improved retention of nutrition. This study remains to be confirmed by larger, more extended controlled trials with MRI confirmation. In twenty patients presented here, however, 85% improved clinically, and the improvement could be correlated fairly well with MRI changes. It would appear, therefore, that there is a role for the application of high-weight, focused lumbar distraction treatment as obtained with the DRS. This type of treatment should be considered as a promising alternative to surgery or long term disability for lumbar disc sufferers.

References

1. Shealy CN, Borgmeyer V. Decompression, reduction and stabilization of the lumbar spine: A non-operative treatment for lumbar disc pain. *Am J Pain Management* 1997;7:23-65.
2. Shealy CN, Leary P. *New Concepts in Back Pain Management, Decompression, Reduction and Stabilization: Pain Management, a Practical Guide for Clinicians*. Boca Raton, FL: Lucie Press; 1993:229-257.
3. April C, Dogaal N. High Intensity Zone Diagnostic sign of painful disc on magnetic resonance imaging. *Br J Radiol*. 1993;66:361-369.
4. Nussli BH, Houghon J, Yu S, Au H. Radial tears of the intervertebral disc: Anatomic appearance, biomechanics, and clinical effects. *Int J Neurotraumatol*. 1997;23:370-384.
5. Anderson G, Schultz A, Nachemson A. Intervertebral disc compression during traction. *Spinal J (Phila Pa)*. 1993;3(2):118-27.
6. Nachemson A, Ericson G. Intradiscal dynamic pressure measurement of lumbar disc. *Scand J Rehabil Med*. 1980;12(suppl):7-16.
7. Ramos C, Martin W. Effects of vertebral axial decompression on intradiscal pressure. *Physiotherapy*. 1994;74:302-302.
8. Onel G, Yuldas M, Sari H, et al. Computerized tomographic investigation of the effects of traction on lumbar disc herniations. *Spine*. 1999;24:44-50.
9. Hutton WC, Emswiler MR, Buckner SD, et al. Analysis of chondroitin sulfate content in lumbar discs in two different stages of degeneration, assessed by discogram. *J Spinal Disord*. 1991;10:47-54.
10. Modic PT, Farnham SJ, Leppinen L, Cardinal E, Boston C. Differentiation of lumbar disc prolapse disc bulges and discs with normal contour but abnormal signal intensity magnetic imaging discographic correlation. *Spine*. 1999;24:44-53.
11. Parnianpour M, Parnianpour TE, Caspell P. Nerve ingrowth into L5 and S1 intervertebral disc in chronic back pain. *Lancet*. 1983;321:108-111.
12. Bogata K, Hiltunen LA. Nutritional pathway of the intervertebral disc. *Spine*. 1981;6:121-126.
13. Modic MT, Steinberg PM, Ross JS, et al. Degenerative disc disease: assessment of changes in vertebral body marrow with MRI imaging. *Radiology* 1983;166:193-199.
14. Luoma IO, Czarola AD, Goldsmith SJ. SPECT and lumbar MRI in back pain with emphasis on changes in end plates in association with changes in end plates in association with disc degeneration. *J Neuroimaging* 1995; 5:79-82.

SUMMARY OF STUDY

Subjects Condition

- Herniated Discs
- Degenerated Discs
- Torn Annulus

Prior to Treatment

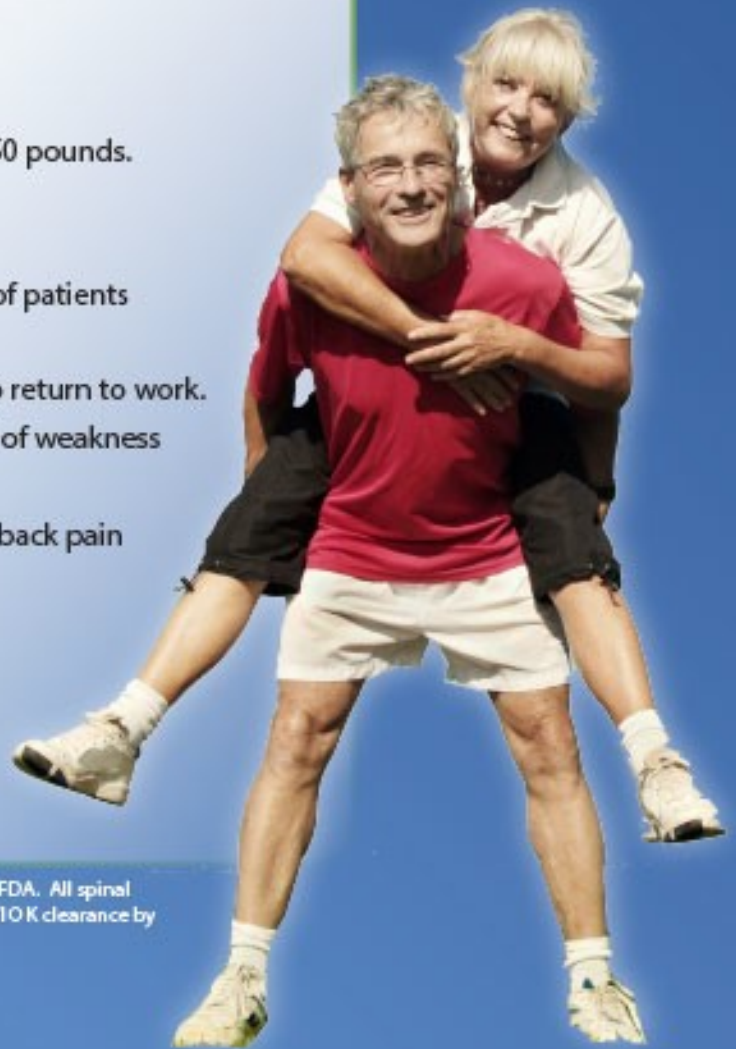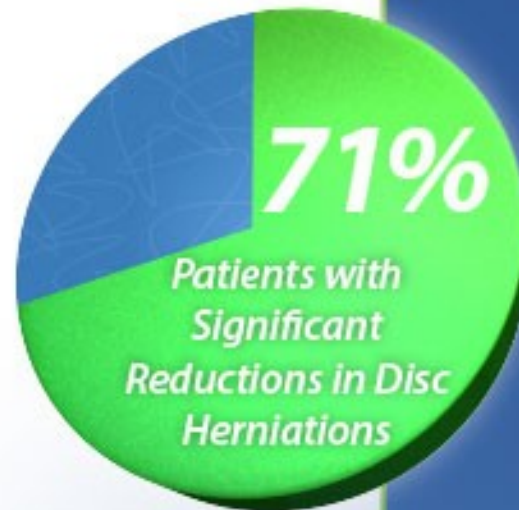- Pain in back and down the leg
- Numbness in legs
- Weakness

5-Week Protocol

- 20 treatments
- Force of Pull = $\frac{1}{2}$ body weight plus 10 lbs
- Force alternated with 30 seconds of relaxation to 50 pounds.

Post Treatment

- Over 90% reduction of nucleus herniation in 71% of patients
- Torn annulus repair is seen in all
- Virtually all subjects have sufficient relief of pain to return to work.
- 71% had significant pain relief and complete relief of weakness
- 90%+ had numbness in the leg disappear
- 86% had "good" to "excellent" relief of Sciatic and back pain
- 28% had rapid relief in as few as 3 treatments
- 85% improved clinically
- Only 6% recurrence rate at 1 year



Individual results may vary. These statements have not been evaluated by the FDA. All spinal decompression devices currently registered with the FDA have received their 510 K clearance by claiming their device is substantially similar to predicate traction devices.